


# International Journal of Multidisciplinary Research in Science, Engineering and Technology

*(A Monthly, Peer Reviewed, Refereed, Scholarly Indexed, Open Access Journal)*



**Impact Factor: 8.206**

**Volume 8, Issue 5, May 2025**



**International Journal of Multidisciplinary Research in  
Science, Engineering and Technology (IJMRSET)**  
(A Monthly, Peer Reviewed, Refereed, Scholarly Indexed, Open Access Journal)

# Cone Beam Computed Tomography Evaluation of Mesial Root Morphology in Mandibular First Molars: An in Vitro Study

**Dr. Harpreet Singh, Dr. Renu Bala Sroa, Dr. Jagvinder Singh Mann**

Dean Research, Professor and Head, Conservative Dentistry and Endodontics, BJS Dental College, Hospital and  
Research Institute, Ludhiana, India

Principal, Professor and Head, Conservative Dentistry and Endodontics, Govt. Dental College and Hospital,  
Amritsar, India

Principal, Professor and Head, Conservative Dentistry and Endodontics, Govt. Dental College and Hospital,  
Patiala, India

**ABSTRACT:** Introduction: The growing awareness among patients about preserving natural teeth has led to an increased demand for endodontic treatment. As the first permanent posterior tooth to erupt, the mandibular first molar is frequently affected by dental caries, often necessitating root canal therapy. A thorough understanding of the root canal morphology, particularly the mesial root, is critical for successful treatment outcomes.

**Aim:** To assess the morphology of mesial root of mandibular first molars using Cone Beam Computed Tomography (CBCT).

**Materials and Methods:** A total of 550 extracted mandibular first molars with fully developed roots were selected for the study. The teeth were arranged in wax molds shaped like dental arches, with 10 teeth per arch. All specimens were subjected to CBCT scanning for evaluation.

**Results:** Analysis revealed that 521 teeth had two canals in the mesial root, while 29 teeth exhibited three canals in mesial root of mandibular first molars

**KEYWORDS:** Cone beam computed tomography, middle mesial canal, mandibular first molars, mesial root, root canal anatomy.

## I. INTRODUCTION

In recent years, there has been a notable paradigm shift in the field of dentistry, with increasing emphasis on conservative approaches aimed at preserving natural dentition. This change is driven not only by advancements in dental materials and technologies but also by a growing awareness among patients regarding the long-term benefits of retaining their natural teeth. Consequently, there has been a substantial rise in the number of cases reporting for endodontic therapy, as clinicians and patients alike strive to avoid extractions whenever possible.

Among the teeth frequently requiring endodontic intervention, the mandibular first molar (MFM) stands out as particularly significant. As the first permanent posterior tooth to erupt, usually around the age of six, it plays a critical role in establishing proper occlusion and guiding subsequent dental eruption. However, due to its early eruption and long functional period, it is also one of the most vulnerable teeth to dental caries, pulp pathology, and restorative challenges. This makes it one of the most commonly treated teeth in clinical endodontics [1].

The success of endodontic treatment is largely dependent on a comprehensive understanding of root canal morphology. Failure to identify, clean, shape, and obturate all canals within a root system remains a leading cause of endodontic failure. The mesial root of the mandibular first molar is especially complex, typically containing two well-recognized





## International Journal of Multidisciplinary Research in Science, Engineering and Technology (IJMRSET)

(A Monthly, Peer Reviewed, Refereed, Scholarly Indexed, Open Access Journal)

canals: the mesiobuccal (MB) and mesiolingual (ML) canals. However, anatomical studies and clinical reports have increasingly highlighted the presence of a third canal — the middle mesial canal (MMC) — situated between the MB and ML canals [2-4]. This canal may be challenging to detect without the aid of enhanced diagnostic tools and magnification, often resulting in its omission during routine procedures[5].

Traditional radiography, being two-dimensional, often fails to reveal such intricacies due to anatomical superimposition. Cone Beam Computed Tomography (CBCT) has emerged as a transformative diagnostic modality in endodontics, offering three-dimensional imaging capabilities with enhanced spatial resolution. Unlike conventional radiographs, CBCT enables clinicians to visualize the internal anatomy of teeth in multiple planes, thereby improving the detection of additional canals and anatomical variations. The purpose of this in-vitro study was to utilize CBCT to evaluate the morphology of mesial root in mandibular first molars, providing clinicians with evidence-based insights that can aid in enhancing diagnostic accuracy and clinical outcomes.

### II. MATERIALS AND METHODS

A total of 550 extracted human mandibular first permanent molars with fully developed roots were collected from various dental clinics and institutions. Teeth with fractures, resorption, incomplete root formation and previous endodontically treated teeth were excluded.

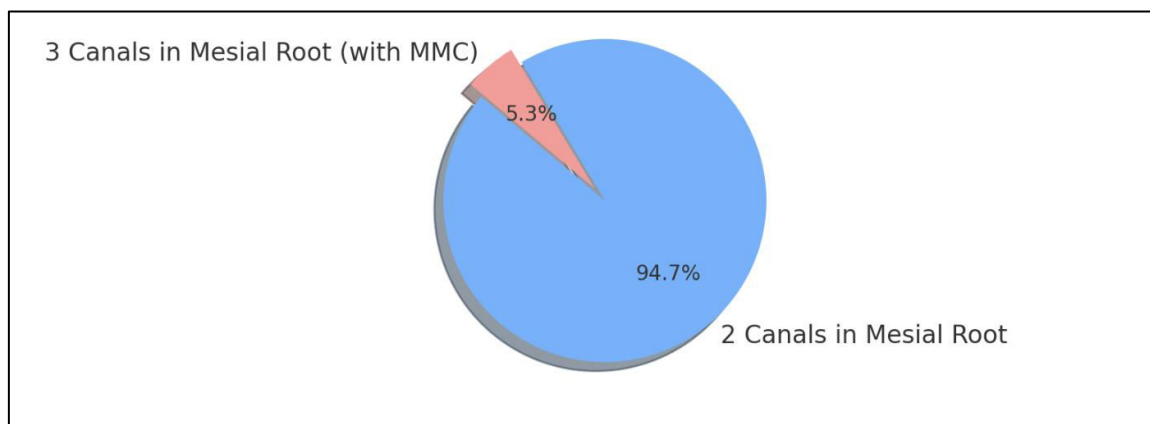
The selected teeth were cleaned of soft tissue debris and mounted in wax molds designed in the shape of dental arches, with 10 teeth per arch to simulate natural alignment and spacing. All specimens were subjected to CBCT scanning using standard endodontic imaging protocols. The images were analyzed to record the number of canals in the mesial root of MFM.

### III. OBSERVATIONS AND RESULTS

Out of the 550 mandibular first molars examined, 521 teeth (94.7%) were found to have two canals in the mesial root. These were typically identified as the mesiobuccal and mesiolingual canals. However, in 29 teeth (5.3%), a third canal was observed between these two main canals, confirming the presence of a middle mesial canal (MMC) (Table 1, Figure 1).

**Table 1: Root canal configuration of mesial root of mandibular first molar**

Canal Configuration	Number of Teeth	Percentage
2 Canals in Mesial Root	521	94.7%
3 Canals in Mesial Root	29	5.3%



**Figure 1: Pie chart showing Root canal configuration of mesial root of mandibular first molar.**



## International Journal of Multidisciplinary Research in Science, Engineering and Technology (IJMRSET)

(A Monthly, Peer Reviewed, Refereed, Scholarly Indexed, Open Access Journal)

### IV. DISCUSSION

The cornerstone of successful root canal therapy lies in the thorough cleaning, shaping, disinfection, and obturation of the entire root canal system. One of the predominant reasons for post-treatment disease and endodontic failure is the presence of missed canals, which may harbour necrotic pulp tissue, bacteria, and their by-products. These residual irritants can lead to persistent periapical inflammation and treatment failure, even in cases where the main canals have been meticulously treated[6].

Among the anatomical variations that contribute to such failures, the presence of more than 2 canals in the mesial root of mandibular first molars has garnered increasing attention [7]. The mesial root is already known for its inherent complexity, often presenting with narrow, curved, and bifurcated canals. The MMC, which is often located between the mesiobuccal and mesiolingual canals, may exist as a separate canal or as a thin isthmus connecting the two main canals[5]. This variation is particularly difficult to detect using conventional radiography due to the two-dimensional superimposition of anatomical structures.

In the present study, a 5.3% incidence of 3 canals was observed in mesial roots of MFM using CBCT. This finding aligns well with prior literature that reports varying incidences ranging from 1% to 46.2%, depending on the population studied, imaging techniques used, and classification criteria[3]. The landmark study by Pomeranz et al. categorized MMCs into three morphological types: fin, confluent, and independent. Fin-type MMCs share connections with either the MB or ML canals, confluent types merge apically with one of the main canals, and independent types have separate apical foramina, making them clinically significant in terms of treatment complexity[5]. Additionally, Vertucci's classification and further anatomical studies have emphasized that the root canal system of mandibular molars is dynamic and often unpredictable. Vertucci noted multiple configurations even within the same root type, underscoring the necessity for clinicians to remain vigilant and adaptable during treatment planning and execution[8].

The incorporation of CBCT technology in this study proved invaluable. Unlike traditional intraoral radiographs, CBCT offers high-resolution, three-dimensional visualization of the tooth and surrounding structures, allowing for a more comprehensive assessment of canal morphology. Its ability to provide sagittal, coronal, and axial views eliminates anatomical noise and overlapping that often obscures additional canals on standard radiographs[9]. In endodontics, this modality is especially useful for detecting anatomical anomalies such as MMCs, C-shaped canals, accessory canals, or complex apical deltas .

From a clinical standpoint, the detection of MMCs demands meticulous attention during access cavity preparation. The developmental groove on the pulpal floor between the MB and ML canals is a key area where MMCs may be located. It is highly recommended that clinicians use dental operating microscopes (DOMs), ultrasonic tips, and micro-openers to explore this groove. Illumination and magnification significantly enhance visualization and tactile feedback, increasing the chances of identifying and negotiating additional canals[10].

Moreover, endodontic education and training programs should emphasize the potential presence of anatomical variants. A deeper understanding of such complexities can not only improve clinical outcomes but also reduce the incidence of re-treatment and surgical interventions. As a preventive measure, routine use of CBCT should be considered in retreatment cases, or in primary treatment where conventional methods suggest anatomical ambiguity.

In conclusion, MFMs especially in their mesial root possess anatomical variations which need careful attention when performing endodontic therapy. Even a seemingly rare anatomical variation, when undetected, can compromise the long-term success of endodontic therapy. Therefore, integrating advanced diagnostic tools, staying informed about anatomical variations, and adopting a meticulous clinical approach are critical steps toward delivering predictable and effective endodontic care.

### V. CONCLUSION

The present study highlights the anatomical complexity of the mesial root of mandibular first molars. Using cone beam computed tomography (CBCT), the incidence of 3 canals was found to be 5.3%, underscoring the need for heightened awareness among clinicians when performing root canal treatments in these teeth.



## International Journal of Multidisciplinary Research in Science, Engineering and Technology (IJMRSET)

(A Monthly, Peer Reviewed, Refereed, Scholarly Indexed, Open Access Journal)

The use of advanced imaging modalities like CBCT, should be encouraged, especially in cases with ambiguous canal anatomy. By incorporating such technologies and a meticulous clinical approach, practitioners can enhance treatment outcomes and reduce the risk of endodontic failure due to missed canals.

### REFERENCES

1. Lee SM, Yu YH, Karabucak B. Endodontic treatments on permanent teeth in pediatric patients aged 6-12 years old. J Dent Sci. 2023 Jul;18(3):1109-1115.
2. Mamat R, Nik Abdul Ghani NR. The Complexity of the Root Canal Anatomy and Its Influence on Root Canal Debridement in the Apical Region: A Review. Cureus. 2023 Nov 18;15(11):e49024.
3. Bansal R, Hegde S, Astekar M. Morphology and prevalence of middle canals in the mandibular molars: A systematic review. J Oral Maxillofac Pathol 2018;22:216-26.
4. Penukonda R, Pattar H, Nambiar P, Al-Haddad A. Middle mesial canal in mandibular first molar: A narrative review. Saudi Dent J 2023;35:468-75.
5. Pomeranz HH, Eidelman DL, Goldberg MG. Treatment considerations of the middle mesial canal of mandibular first and second molars. J Endod 1981;7:565-8.
6. Tabassum S, Khan FR. Failure of endodontic treatment: The usual suspects. Eur J Dent. 2016 Jan-Mar;10(1):144-147.
7. Manik K, Ikhar A, Patel A, Chandak M, Bhopatkar J, Rathod P, Bhojwani PR. Anatomical Variations in Mandibular Molars: Focus on Midmesial Canals. Cureus. 2024 Jun 5;16(6):e61711
8. Yang Y, Jiang C, Chen M, Zeng J, Wu B. Vertucci's root canal configuration of 11,376 mandibular anteriors and its relationship with distolingual roots in mandibular first molars in a Cantonese population: a cone-beam computed tomography study. BMC Oral Health. 2022 Apr 16;22(1):130.
9. Kumar M, Shanavas M, Sidappa A, Kiran M. Cone beam computed tomography - know its secrets. J Int Oral Health. 2015 Feb;7(2):64-8
10. Mendes EB, Soares AJ, Martins JNR, Silva EJNL, Frozoni MR. Influence of access cavity design and use of operating microscope and ultrasonic troughing to detect middle mesial canals in extracted mandibular first molars. Int Endod J. 2020 Oct;53(10):1430-1437





INTERNATIONAL  
STANDARD  
SERIAL  
NUMBER  
INDIA



# INTERNATIONAL JOURNAL OF MULTIDISCIPLINARY RESEARCH IN SCIENCE, ENGINEERING AND TECHNOLOGY

| Mobile No: +91-6381907438 | Whatsapp: +91-6381907438 | [ijmrset@gmail.com](mailto:ijmrset@gmail.com) |

[www.ijmrset.com](http://www.ijmrset.com)